

Two-stage Reconstruction of Tumor Resection Wounds with PELNAC™



Ryoichi Kamide, M.D.

Director of Hihuno Clinic Ningyocho
Former Director of Department of Dermatology, Daisan Hospital,
The Jikei University School of Medicine

Introduction

Tissue defects due to resection of skin tumors can be reconstructed by various techniques, including simple suture closure, skin flaps and skin grafting. However, two-stage reconstruction—in which tissue defects are initially covered with artificial dermis to promote formation of granulation tissue, followed by skin grafting—is often beneficial for elderly patients and special operative sites.

Two-stage reconstruction has the following advantages: (1) secondary wounds due to skin flaps are avoided; (2) surgery can often be performed under local anesthesia; (3) for malignant tumors, reconstruction can be performed after confirming the absence of residual tumor cells in the resection margin; (4) the procedures are easy to carry out and unlikely to cause necrosis of skin grafts or flaps; and (5) a cosmetically favorable appearance can ultimately be achieved. On the other hand, this method has certain disadvantages, including: (1) it takes two to three weeks for granulation tissue to form; (2) changing of the dressing during that period can become burdensome; (3) two surgeries must be performed; and (4) the tissue durability may not be very good.

For elderly patients, emphasis is often placed on minimizing the invasiveness, while the appearance and tissue durability have relatively lower priority. In addition, elderly patients have the time to undergo surgical procedures that are broken into several stages and are performed over several weeks. A longer interval, e.g., 5-6 weeks until skin grafting, may permit ample formation of granulation tissue. Thick granulation tissue contracts firmly and reduces the size of wounds, sometimes even to approximately half the size of the resected area, which is advantageous in terms of the appearance. It also results in better durability of at weight-bearing areas such as the heel.

Case 1

A female patient in her 80s, with an amelanotic melanoma of the right heel (Fig. 1a). Almost the entire heel (6 cm in diameter) was resected under local anesthesia, leaving a small amount of adipose tissue. PELNAC was put in place, fixed and compressed without tie-over fixation. Four days after the surgery, the patient was discharged from the hospital in an ambulatory state. After 6 weeks, thick granulation tissue had formed (Fig. 1b), and full-thickness skin grafting from the inguinal region was performed under local anesthesia. The skin graft was initially elevated due to granulation tissue contraction (25 days after skin grafting, Fig. 1c), but it became flat after 14 months (Fig. 1d) and had no impact on walking.

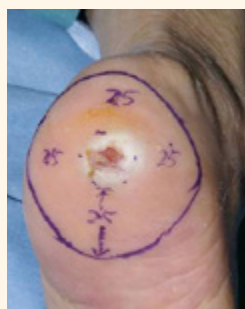

Fig. 1a
Amelanotic melanoma of the heel. The entire heel was resected.

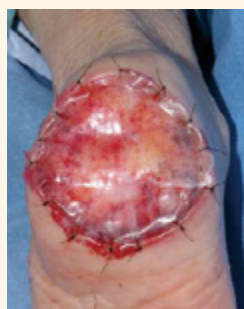

Fig. 1b
Covered with PELNAC. Formation of granulation tissue was favorable.

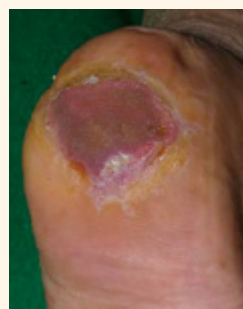

Fig. 1c
25 days after full-thickness skin grafting. The skin graft had taken well.

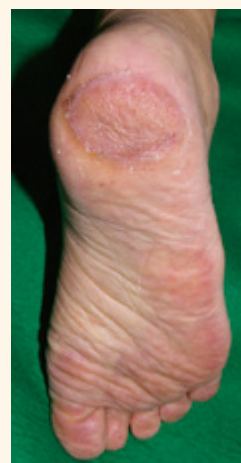

Fig. 1d
14 months after full-thickness skin grafting.

The patient was hospitalized on June 11. The lesion was resected with a 25-mm surgical margin under local anesthesia, leaving adipose tissue immediately above the calcaneus. The skin defect was covered with PELNAC, which was fixed and compressed without tie-over fixation. After surgery, the skin graft site followed a favorable course, but ultrasonography (August 15) indicated a swollen, 11×19 mm lymph node with blood-flow signals in the right inguinal region. The patient's family was not in favor of aggressive treatments such as lymphadenectomy and chemotherapy because of the patient's age, and she is currently under observation.

Case 2

A female patient in her 60s, with an acral lentiginous melanoma extending from the right hypothenar eminence to the base of the 4th and 5th toes (Fig. 2a). The melanoma was resected with a wide surgical margin under local anesthesia, and the wound was covered with PELNAC (Fig. 2b). Favorable granulation tissue formed beneath the PELNAC (Fig. 2c). Two months after full-thickness skin grafting, the skin graft had shrunk without contracture of the toes and did not interfere with walking (Fig. 2d).

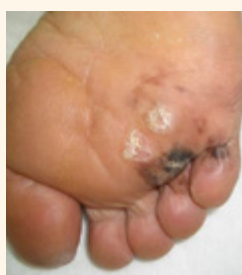

Fig. 2a

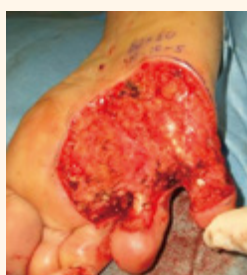

Fig. 2b

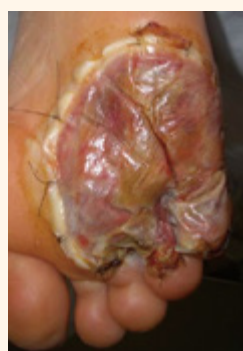

Fig. 2c

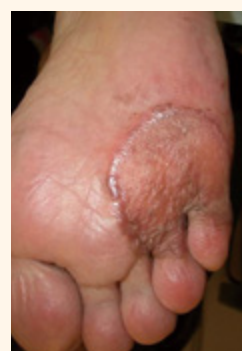

Fig. 2d

Case 3

A female patient in her 60s, with a 6-cm diameter sebaceous gland carcinoma in the parietal area (Fig. 3a). The carcinoma was resected with a 1-cm surgical margin under local anesthesia, and the wound was covered with PELNAC (Fig. 3b, 3 days after surgery). After 5 weeks, an approximately 2-mm width of the scar circumscribing the good granulation was removed (Fig. 3c), and full-thickness skin grafting from the inguinal region was performed. After 2 months, the skin graft shrank to about half the size of the initially resected area (Fig. 3d) and could be covered with surrounding hair, disguising the area of hair loss.

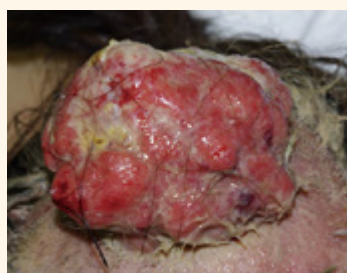

Fig. 3a

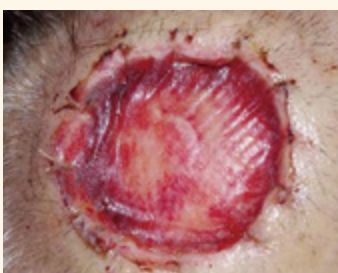

Fig. 3b

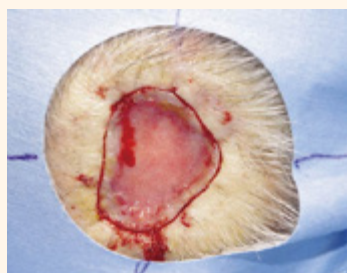


Fig. 3c

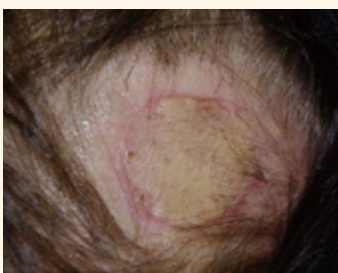

Fig. 3d

Case 4

A male patient in his 40s, with melanoma under the nail plate of the right index finger (Fig. 4a). The melanoma was resected above the periosteum with a 5 mm surgical margin, and the wound was covered with PELNAC. After 5 weeks, the patient underwent full-thickness skin grafting from his palm (Fig. 4b, 2 weeks after skin grafting). The skin graft had a nail-like appearance (Fig. 4c, 1 month after skin grafting). Two years and 4 months after surgery (Fig. 4c), the skin graft had shrunk and the distal phalanx had tapered, but the appearance was not particularly unusual.

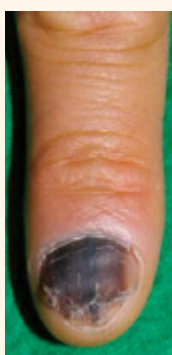

Fig. 4a

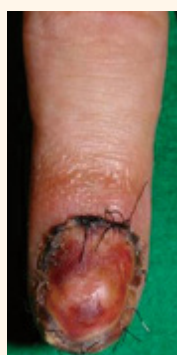

Fig. 4b

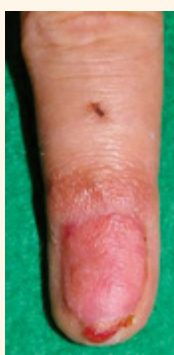

Fig. 4c

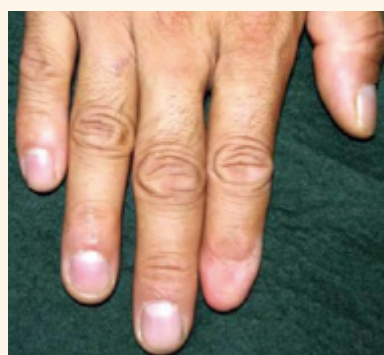


Fig. 4d

Summary

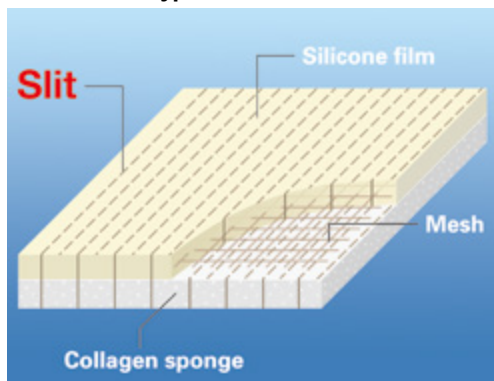
Two-stage reconstructive surgery, in which skin defects due to tumor resection are temporarily covered with PELNAC, followed by free skin grafting performed after thick granulation tissue has formed, requires approximately 1 month. However, it is convenient, cosmetically more favorable than one-stage skin grafting, and functionally commensurate with skin flaps. It is a useful treatment option for elderly patients and special operative sites.

Product image

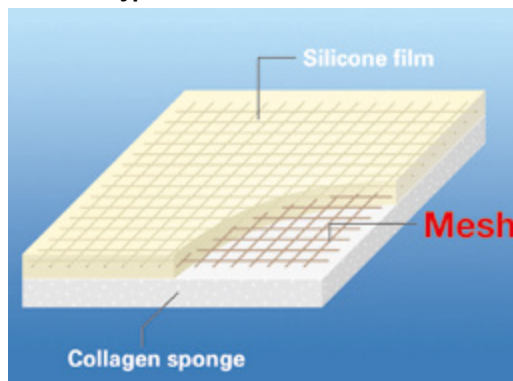


Variation

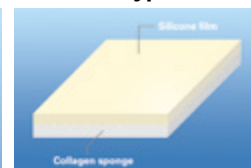
Fenestrated type



Fortified type



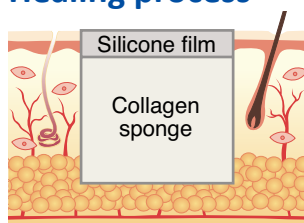
Standard type



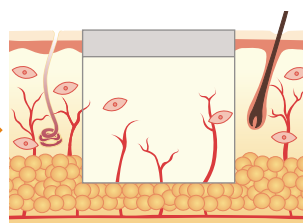
Single layer type



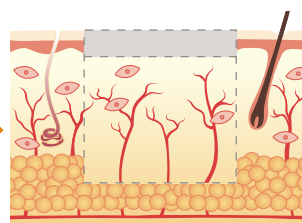
Healing process



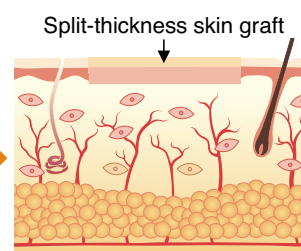
PELNAC is applied to full-thickness skin defects.



Fibroblasts and capillaries invade and infiltrate into the spaces in collagen sponge.



Collagen sponge is gradually replaced by newly synthesized collagen into dermis-like tissue.



After 2-3 weeks, the silicone film is peeled off, leading to wound closure with split-thickness skin graft.

GUNZE

**GUNZE LIMITED
Medical Division**

<http://www.gunze.co.jp/e/medical/>

● Japan

TOKYO OFFICE

Nihonbashi2-10-4, Chuo-ku, TOKYO 103-0027 Japan
Tel: +81-3-3276-8718 Fax: +81-3-3276-8696

● Europe

GUNZE INTERNATIONAL EUROPE GmbH

Oststraße 80, 40210 Düsseldorf, Germany
Tel. +49 211 36 13 971 Fax. +49 211 36 13 164

● Asia Pacific

GUNZE MEDICAL DEVICES (SHENZHEN) LIMITED

Room 802, Kerry Center, 2008 Renminnan Rd., SHENZHEN 518001 P.R. China
Tel. +86-755-8230-0553 Fax. +86-755-8230-0469

● U.S.A.

GUNZE INTERNATIONAL USA, INCORPORATED

5 West 37th Street, Suite 800 New York, NY, 10018, U.S.A.
Tel. +1-212-354-9060 Fax. +1-212-354-6171